



上海交通大学医学院附属第九人民医院
Shanghai Ninth People's Hospital affiliated to Shanghai JiaoTong University, School of Medicine



性别相关的整形美容/重建手术

程 辰

上海交通大学医学院附属
第九人民医院 整复外科



上海交通大学医学院附属第九人民医院 整复外科

1951年张涤生院士创建 我国整复外科发源地之一

➤ 张涤生院士：

- 1982年完成世界首例一期完成的全阴茎再造手术
- 1988年国家发明三等奖：应用显微外科技术一次完成阴茎再造

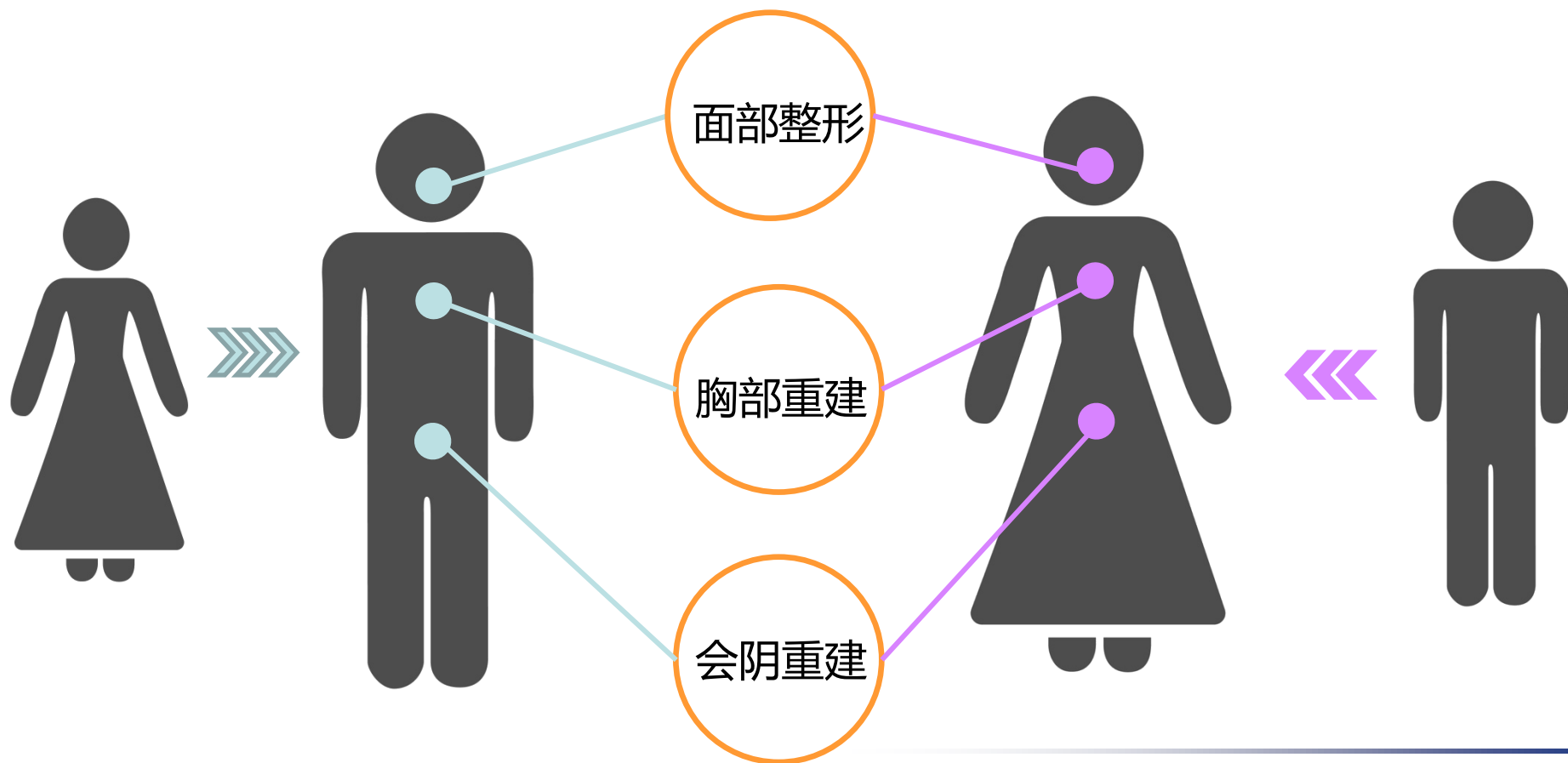
➤ 学科评价：

首批国家重点学科，国家211工程重点学科、上海市重中之重医学临床中心

学科声誉榜，全国排名第一（11年蝉联）

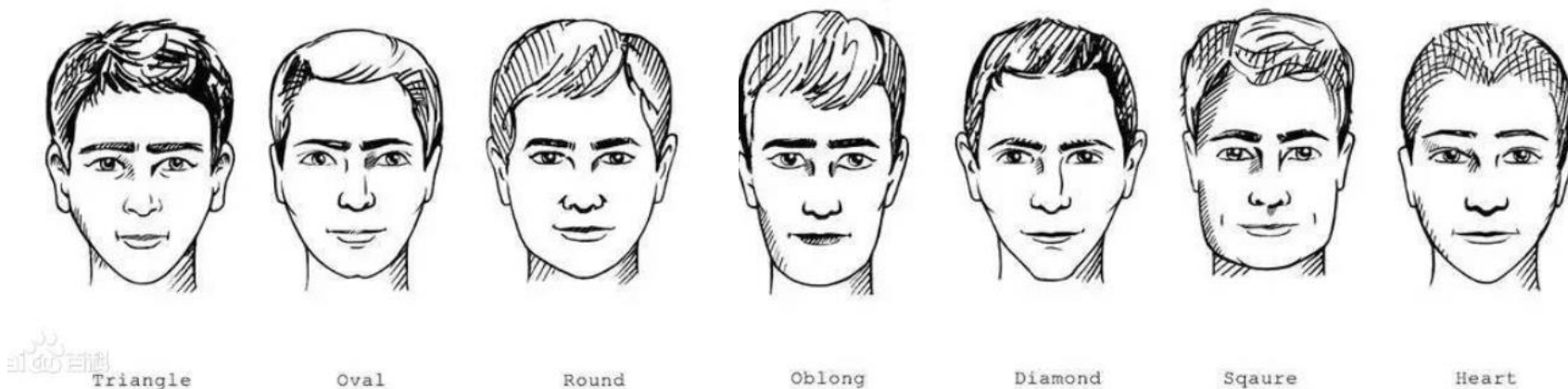
科技创新力，全国排名第一（7年蝉联）

性别整形手术



面部整形

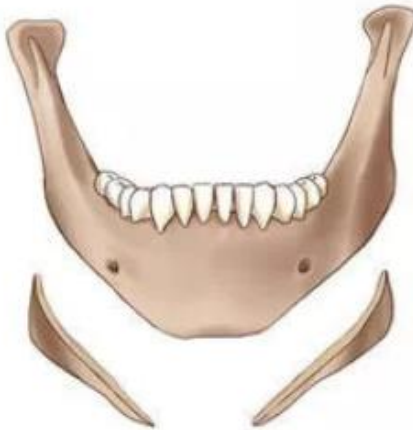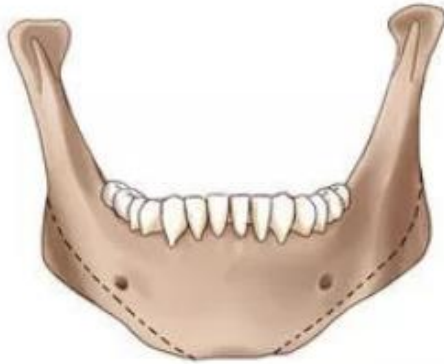- 波契将人类的脸型分为十种（1）圆形脸型；（2）椭圆形脸型；（3）卵圆形脸型；（4）倒卵圆形脸型；（5）方形脸型；（6）长方形脸型；（7）梯形脸型；（8）倒梯形脸型；（9）菱形脸型；（10）五角形脸型



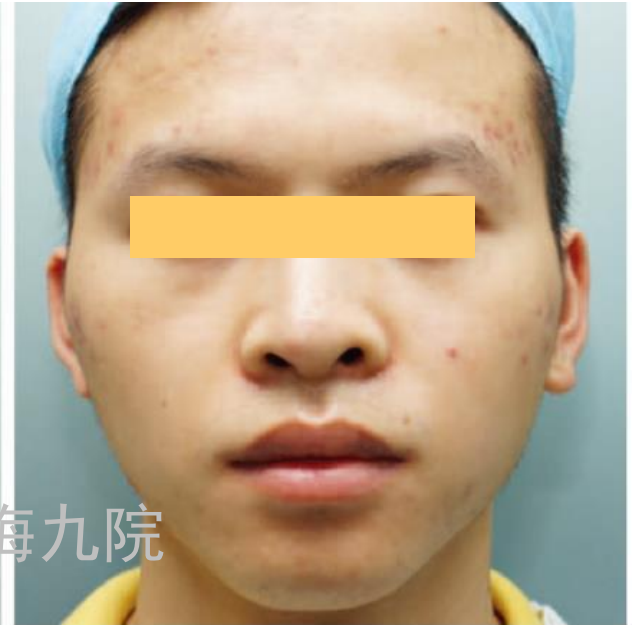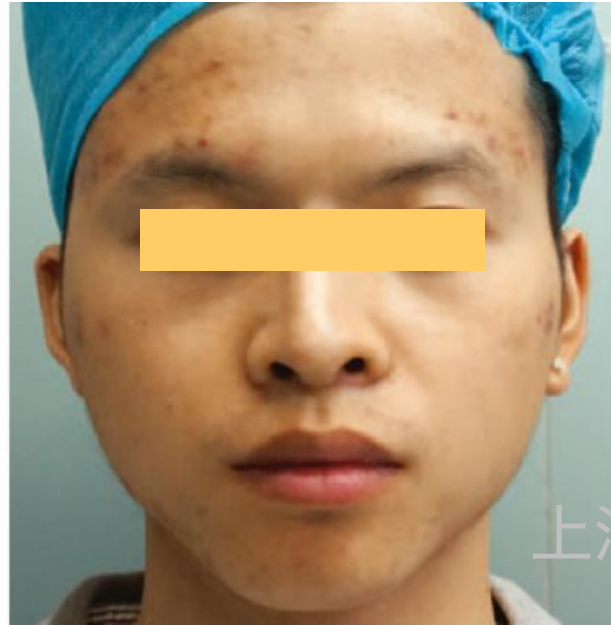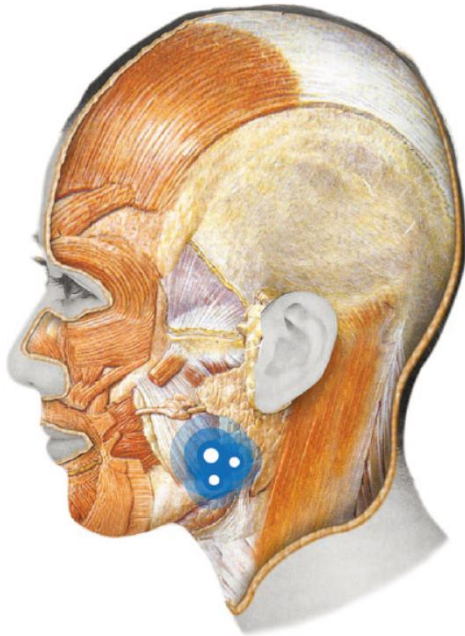
轮廓整形(女性化)



轮廓整形：下颌骨截骨



轮廓整形：瘦脸针



上海九院

轮廓整形(男性化)

Defining the Jaw & Jawline with Fillers



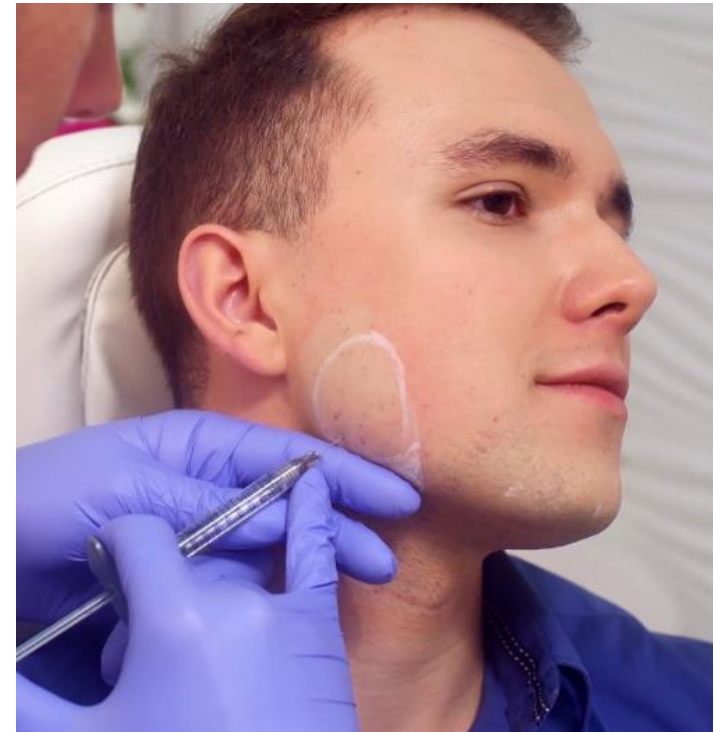WOMEN

For women, it's all about subtle to strong contouring and enhancement, similar to what's often achieved with makeup.



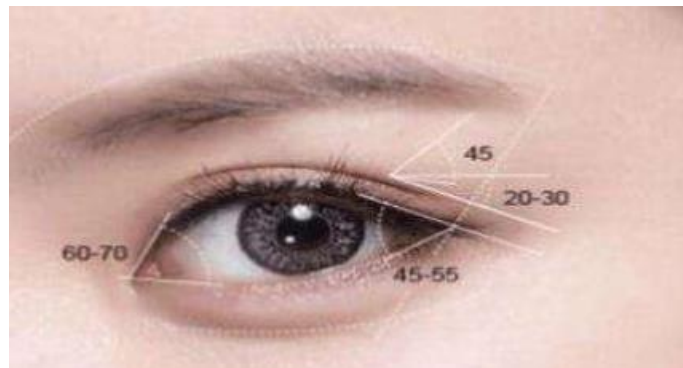
MEN

For men, the goal is to sculpt a chiseled jawline, focusing on angles and straight lines that enhance the naturally masculine bone structure.



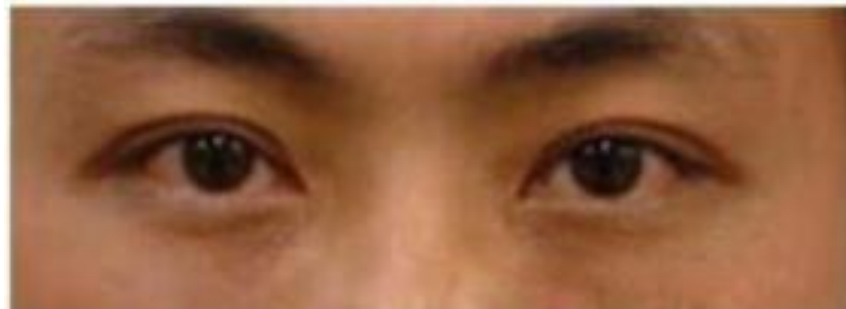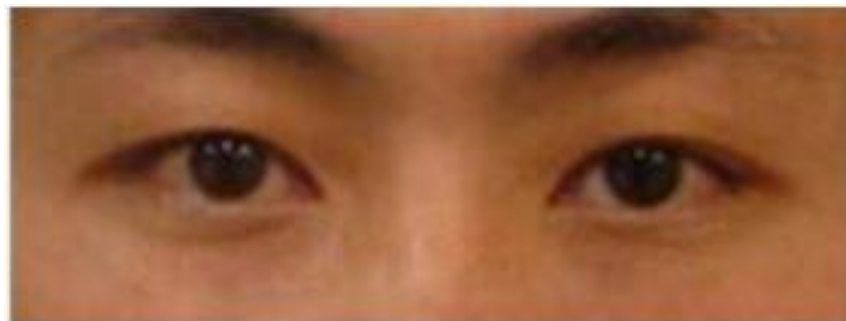五官之眼整形

➤ 双眼皮：诊疗量最大的美容手术



有神、灵动、妩媚

男性双眼皮：深邃、成熟感



编注：医生的意思是这些明星的五官漂亮，仅供内部学习交流用，请勿曲解

五官之鼻整形



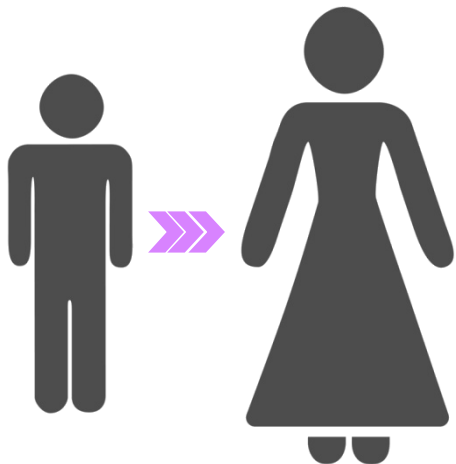
鼻背弧度，鼻尖微翘




鼻背高直，鼻尖向下

编注：医生的意思是这些明星的五官漂亮，仅供内部学习交流用，请勿曲解

胸部整形

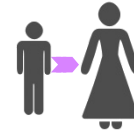


- 假体隆胸
- 自体脂肪隆胸

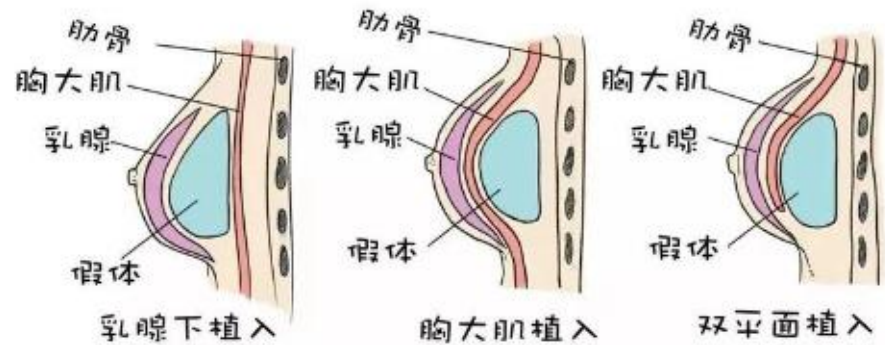


- 乳腺切除&乳头重建

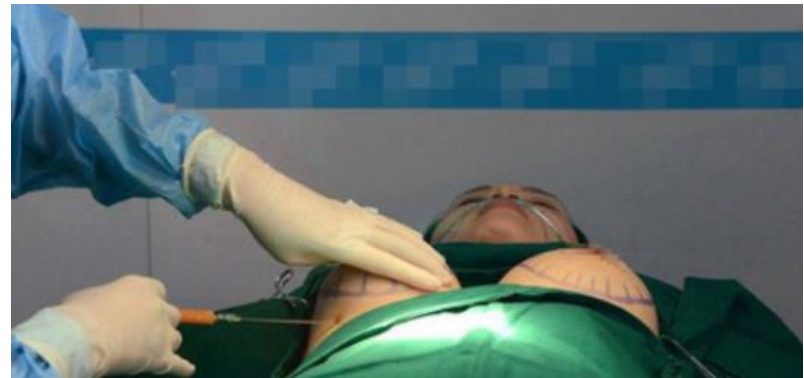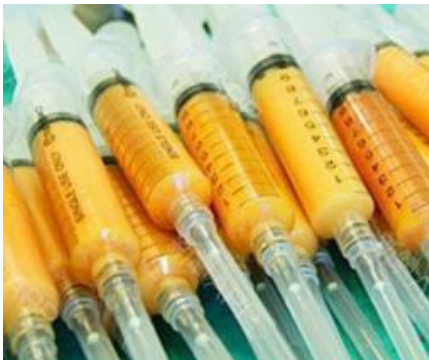隆胸手术



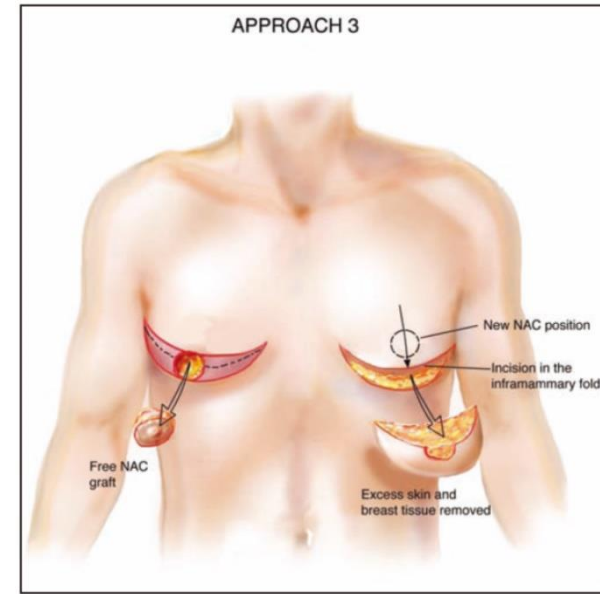
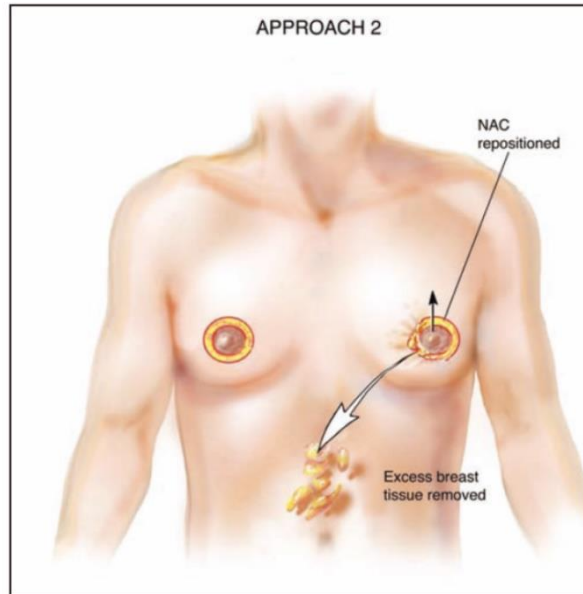
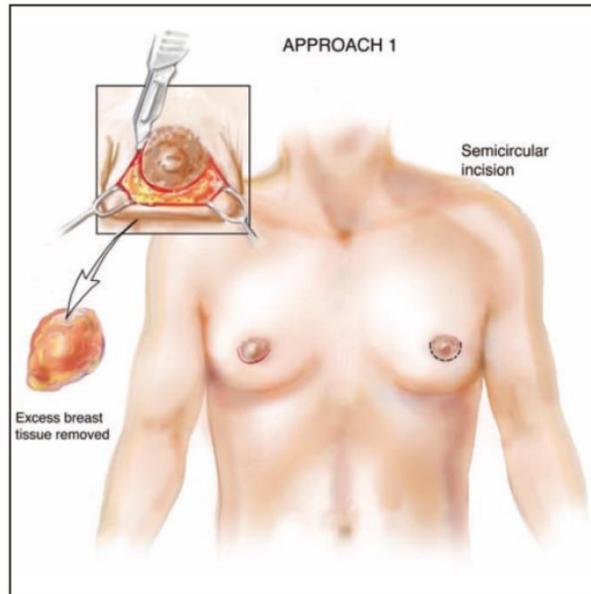
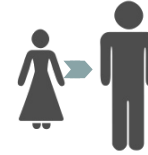
假体



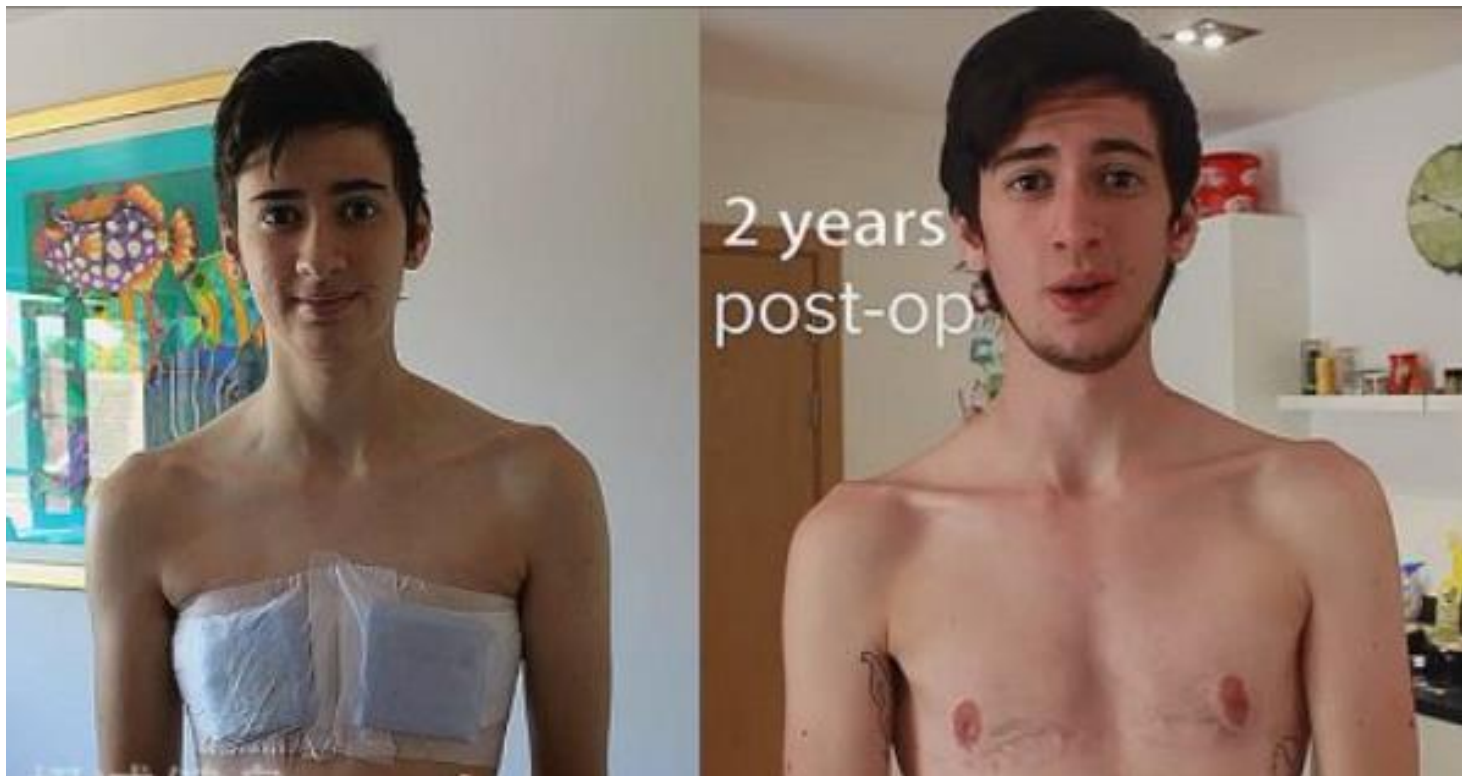脂肪



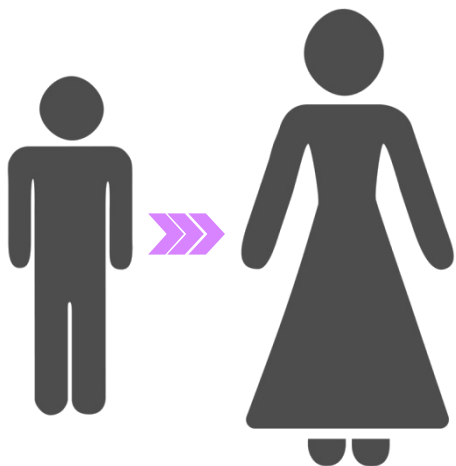
乳腺切除术




乳腺切除术



会阴区重建

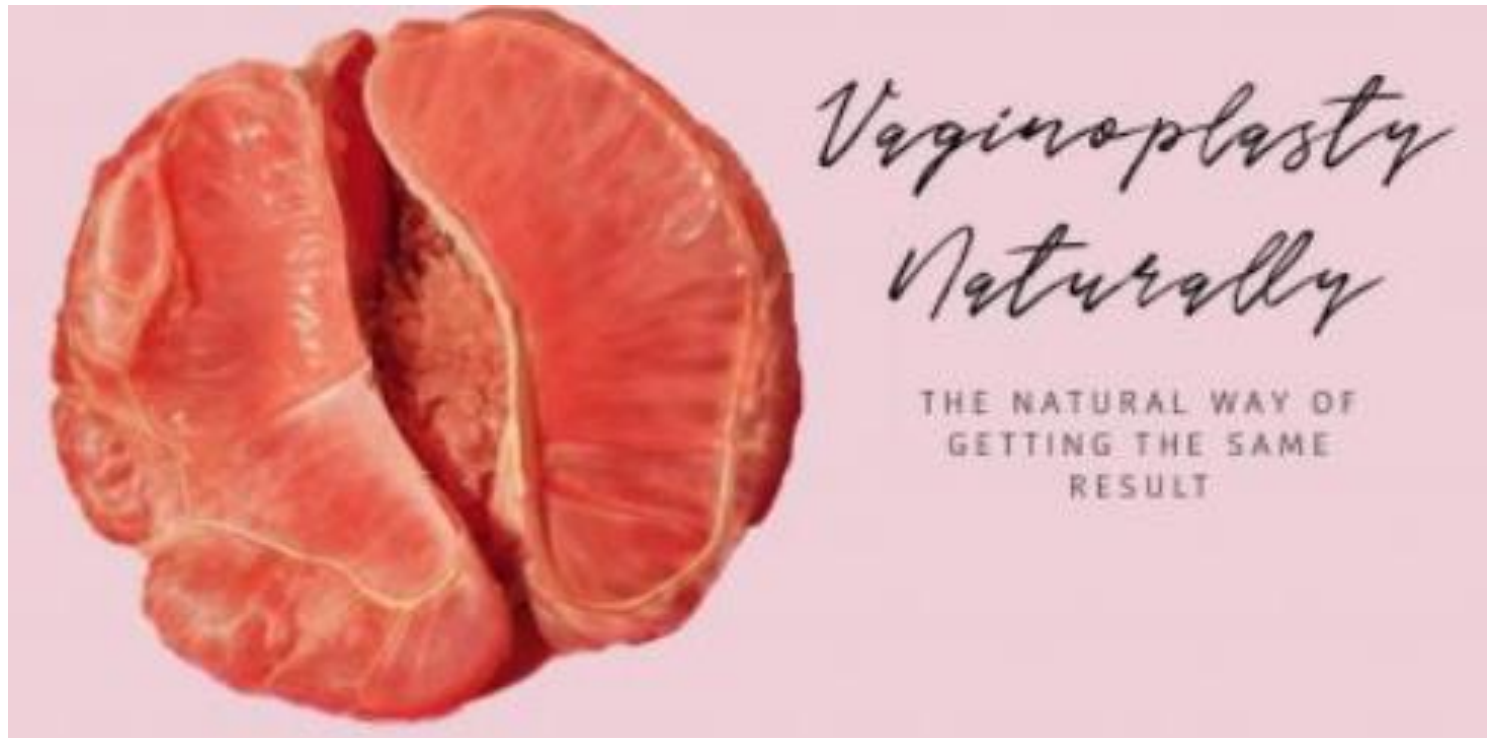

- 外阴阴道成形
- 阴茎睾丸切除



- 阴茎成形/再造手术
- 阴道切除手术

外阴阴道成形





阴茎成形

Forearm Flap in One-Stage Reconstruction of the Penis

Ti-Sheng Chang, M.D., and Wen-Yi Hwang, M.D.
Shanghai, People's Republic of China

Traumatic or surgical amputation of the penis, congenital penile absence, micropallus, and male pseudohermaphroditism are physiologically and psychologically intolerable to patients. Consequently, reconstruction becomes mandatory.

In classical phalloplasty, the long period of reconstruction (6 to 12 months) and multiple procedures (3 to 5 stages) are physically and economically difficult for patients, even though a penis thus reconstructed is physiologically, cosmetically, and psychologically acceptable, permitting both marriage and sexual activity.

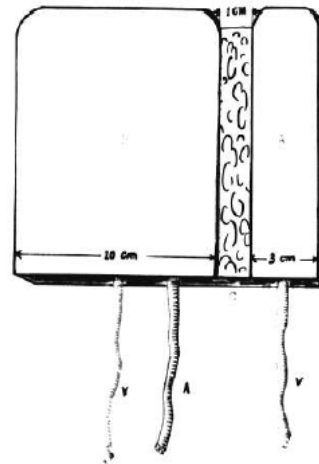
Since the introduction of microsurgical technique, one-stage penile reconstruction has become possible by making use of an immediately vascularized skin flap. With this technique, the forearm free skin flap, which is soft, uniformly thin in subcutaneous tissue, and has a long vascular pedicle, seems to be an ideal donor.

We have so far performed 7 cases of penile reconstruction utilizing the radial skin flap to immediately reconstruct the urethra and the penis in a single stage with complete success.

SURGICAL TECHNIQUE

Two surgical teams are necessary, one for forearm skin flap preparation and another for costal cartilage removal and preparation of the recipient sites, including dissection of the amputated penis stump, preparation of recipient vessels in the inguinal region, and a suprapubic cystostomy for urinary drainage.

flap 11 to 12 cm in length and 14 to 15 cm in width is designed (Fig. 1). Three portions are divided on the flap in order to allow simultaneous



252

PLASTIC AND RECONSTRUCTIVE SURGERY, August 1984

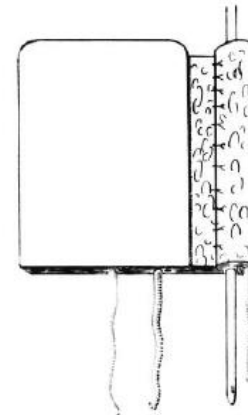
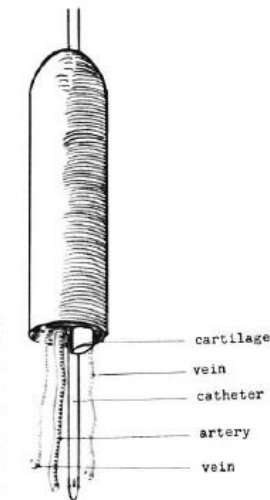


Fig. 2. Segment A is microscopically sutured to form the new urethra.

urethral and penile reconstruction. The larger segment of the flap (B), which is 10 to 11 cm in width, is positioned in the radiodorsal aspect of the distal forearm and incorporates the radial artery and cephalic vein, which courses approximately 1 cm laterally to it. The smaller segment (A), which is 2.5 to 3 cm in width, is used for the formation of the new urethra. Between these two flaps, there is an area (C) that is 1 to 1.5 cm in width, and this is deepithelialized. Thus the larger, more radial flap reconstructs the penis and contains within it the smaller (more ulnar), tubed flap that immediately reestablishes urethral continuity. The deepithelialized portion is intended to increase the area of tissue contact

the overlapping skin edge to the urethral incision and better modeling of the glans (Figs. 1 and 2).

It should be pointed out that in our first two cases only the radial artery and adjacent cephalic vein were utilized in the penile-urethral reconstruction. In these early cases, the vascular supply appeared inadequate in venous return and there was vesicle formation around the distal urethral flap, despite the fact that the flap ultimately



PLASTIC AND RECONSTRUCTIVE SURGERY, August 1984

九院团队：1982-2020

阴茎成形/再造适应症

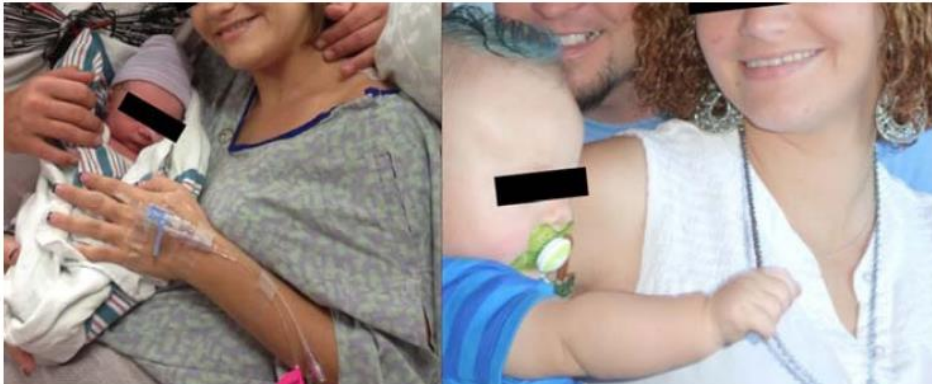- 跨性别群体
- 性发育异常
- 外伤：烧伤、电击伤等

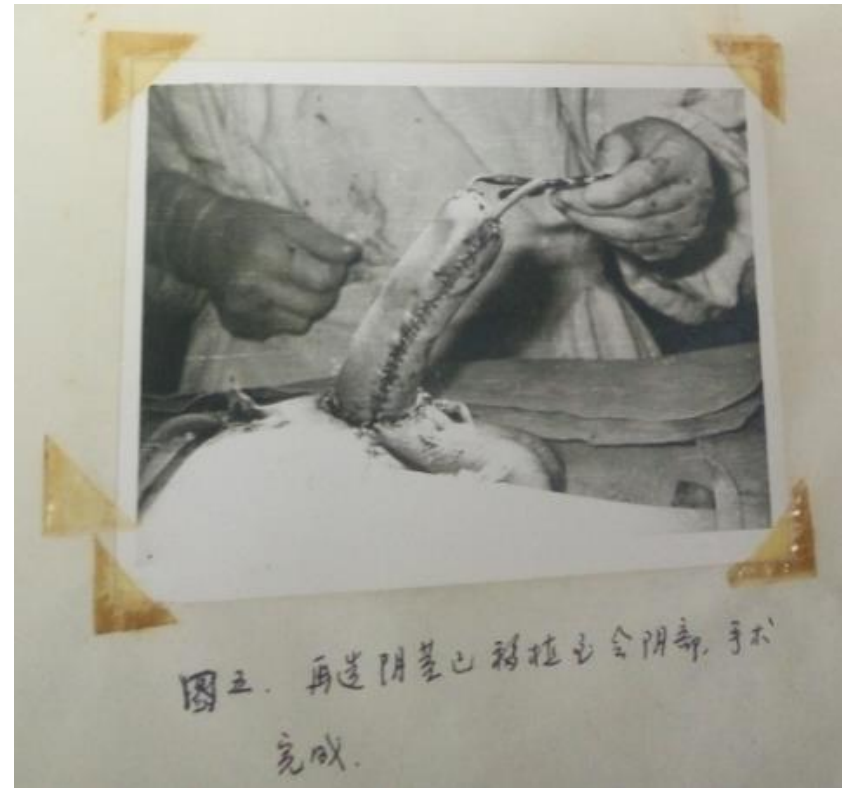
再造阴茎的功能

CLINICAL PAPER

World's First Baby Born Through Natural Insemination by Father With Total Phalloplasty Reconstruction

Anandev N. Gurjala, MD, Rahim S. Nazerali, MD, Ali Salim, MD, and Gordon K. Lee, MD





中国案例：1983年一期
再造，1987年完成生育

真正的世界第一例

Annals of Plastic Surgery Comment on World's First Baby Born Through Natural Insemination by Father With Total Phalloplasty Reconstruction —Manuscript Draft—

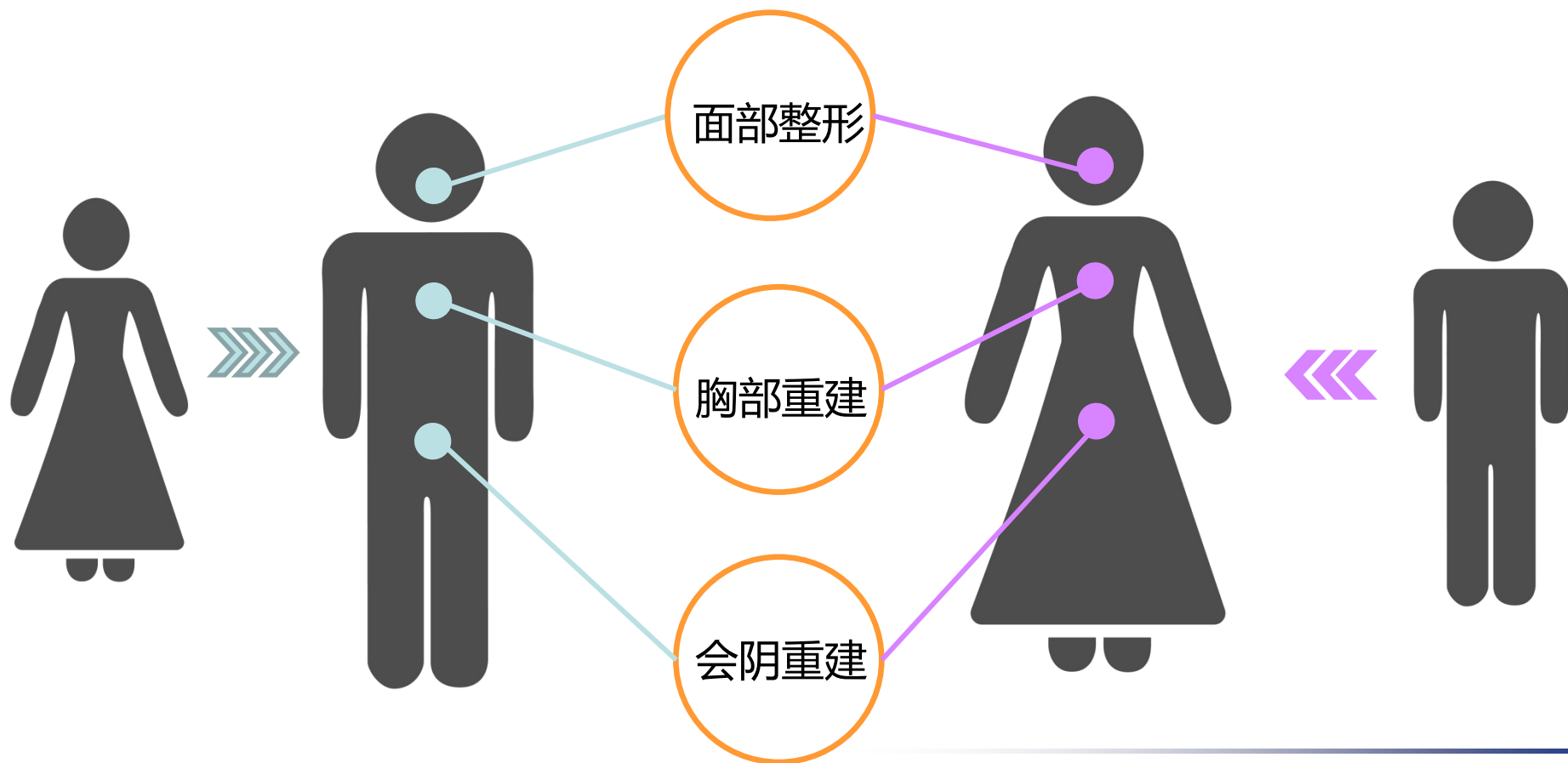
Manuscript Number:	
Full Title:	Comment on World's First Baby Born Through Natural Insemination by Father With Total Phalloplasty Reconstruction
Article Type:	Letter to the Editor
Keywords:	phalloplasty; natural conception; childbirth
Corresponding Author:	Yang Liu, Ph.D., M.D. Shanghai Jiao Tong University School of Medicine Affiliated 9th People's Hospital Shanghai, Shanghai CHINA
Corresponding Author Secondary Information:	
Corresponding Author's Institution:	Shanghai Jiao Tong University School of Medicine Affiliated 9th People's Hospital
Corresponding Author's Secondary Institution:	
First Author:	Kaixiang Cheng, M.D.
First Author Secondary Information:	
Order of Authors:	Kaixiang Cheng, M.D. Chen Cheng, M.D. Fuguo Chen, M.D. Sunxiang Ma, M.D. Yang Liu, Ph.D., M.D.
Order of Authors Secondary Information:	
Manuscript Region of Origin:	CHINA
Abstract:	

传承与创新

- FtM患者的理想方案
阴道粘膜预制尿道：解决长期排尿问题



性别整形手术：从美容到功能重建



激素替代治疗

- 个性化治疗：激素、抗激素
- 重视安全性：激素相关的疾病



解决途径：定期的监测和随访，
科学合理的用药



上海交通大学医学院附属第九人民医院

Shanghai Ninth People's Hospital affiliated to Shanghai JiaoTong University, School of Medicine



谢谢聆听！

微博

仅供科普娱乐



九院整形程辰医生



好大夫

可提供免费三次医疗咨询，
可按需设隐私



程辰

上海交通大学医学院附属
第九人民医院 整复外科



小红书

仅供科普娱乐



标记我的生活

